



CLINICAL RESEARCH

Laparotomy-assisted endoscopic removal of gastrointestinal foreign bodies: Evaluation of this technique and postoperative recovery in dogs and cats

Veronica Cola DVM, PhD  | Chiara Ferrari DVM |
Sara Del Magno DVM, PhD, DECVS (Small Animal)  |
Armando Foglia DVM, PhD | Stefano Zanardi DVM |
Luca Ciammaichella DVM | Ombretta Capitani DVM | Marco Pietra DVM, PhD |
Luciano Pisoni DVM, PhD

Department of Veterinary Medical Sciences, University of Bologna, Bologna, Italy

Correspondence

Sara Del Magno, Department of Veterinary Medical Sciences, University of Bologna, 40064 Ozzano dell'Emilia, Bologna, Italy.
Email: sara.delmagno@unibo.it

Abstract

Objective: To compare the outcome of the laparotomy-assisted endoscopic removal (LAER) of gastrointestinal foreign bodies (FBs) with traditional enterotomy, and to determine which factors affected the ability to remove FBs.

Study design: Retrospective observational study.

Sample population: Dogs and cats ($n = 81$) with gastrointestinal FBs.

Methods: Dogs and cats were divided into Group 1 (LAER, $n = 40$) and Group 2 (Enterotomy, $n = 41$). The localization and characteristics of the FBs (sharp or blunt; discrete or linear; single or multiple) were evaluated statistically to identify the factors that affected the ability of LAER to remove, partially or completely, the FBs (χ^2 test). The length of the postoperative stay, postoperative analgesia, and resumption of spontaneous feeding were compared between groups (Mann-Whitney U -test). Short-term follow up (14 days) was recorded.

Results: Laparotomy-assisted endoscopic removal allowed complete or partial removal of FBs in 35/40 dogs and cats, regardless of the characteristics or the localization of the FBs. The presence of intestinal wall damage ($p = .043$) was associated with the conversion to an enterotomy. Group 1 required a shorter postoperative hospital stay ($p = .006$), less need for analgesia ($p < .001$), and experienced a faster resumption of spontaneous feeding ($p = .012$), and similar complication rate to Group 2.

Abbreviations: LAER, laparotomy-assisted endoscopic removal FBs foreign bodies; VCOG-CTCAE, Veterinary Cooperative Oncology Group-Common Terminology Criteria for Adverse Events.

Marco Pietra and Luciano Pisoni both contributed equally to the manuscript.

This is an open access article under the terms of the [Creative Commons Attribution-NonCommercial](https://creativecommons.org/licenses/by-nc/4.0/) License, which permits use, distribution and reproduction in any medium, provided the original work is properly cited and is not used for commercial purposes.

© 2024 The Author(s). *Veterinary Surgery* published by Wiley Periodicals LLC on behalf of American College of Veterinary Surgeons.

Conclusion: Laparotomy-assisted endoscopic removal resulted in a faster postoperative recovery when compared with an enterotomy. The FBs' characteristics or localization did not affect the efficacy of the technique to remove FBs.

Clinical significance: Laparotomy-assisted endoscopic removal allows the removal of a variety of FBs, avoiding intestinal incision and resulting in a fast postoperative recovery.

1 | INTRODUCTION

Gastrointestinal foreign bodies (FBs) are a common occurrence in dogs and cats, and their removal is often necessary to prevent life-threatening conditions.^{1–3} Mechanical obstruction caused by FBs compromises the blood supply to the intestinal wall, causing luminal distension and, if left untreated, the intestinal stasis could lead to intestinal wall edema, mucosal ischemia with progressive necrosis, and possibly perforation with septic peritonitis.^{4,5}

Endoscopic retrieval of FBs is usually preferred to surgical removal owing to its effectiveness, its minimal invasiveness, and the fact that it requires a shorter hospital stay.^{1,6,7} The endoscopic removal of gastrointestinal FBs is recommended for esophageal and gastric FBs, and enterotomy is usually recommended in the case of intestinal FBs.^{1,6–9} In veterinary medicine, the factors predicting the conversion from a standard endoscopy to the surgical removal of upper gastrointestinal FBs have not been reported, whereas in human medicine, age, location, size, and longer impaction time are well known risk factors.¹⁰ Major complications after enterotomy are uncommon, with wound dehiscence and septic peritonitis reported in 2%–12% of the cases. Death is rare and is observed in 3% of the cases.^{5,11–13} Mild or temporary complications occur more frequently after enterotomy, and they can affect postoperative recovery time (e.g., postoperative ileus or retarded resumption of spontaneous feeding up to 24 h).^{5,11–13}

Laparotomy-assisted endoscopic removal of gastrointestinal FBs has recently been described in dogs and cats.⁹ This technique involves a combination of exploratory laparotomy and endoscopy, providing direct access to the FB and allowing its safe removal without an enterotomy, thus reducing the length of hospital stay when compared with an enterotomy. Demars et al. reported a good outcome, with an effectiveness of 43% (animals not receiving enterotomy), and only few minor postoperative complications (8%), namely wound discharge and mild esophagitis.⁹ Furthermore, this technique has only been described in a small sample population and, to date, it has not been reported which

FB characteristics influence the effectiveness of the technique, which animals are the best candidates for this procedure, and whether this technique requires less postoperative analgesic therapy.⁹

The first aim of this study was therefore to investigate which factors were associated with the complete or partial removal of FBs or with the necessity of conversion to enterotomy.

The second aim of the study was also to compare the outcome of laparotomy-assisted endoscopic removal (LAER) with a traditional enterotomy. Based on the authors' clinical experience, the LAER of FBs may have a more favorable outcome with a faster postoperative recovery when compared with a traditional enterotomy for FB removal. Specifically, the authors' hypotheses were that dogs and cats treated with LAER required less analgesic therapy, experienced a prompt resumption of spontaneous feeding, and a shorter hospital stay, and sustained fewer postoperative complications.

2 | MATERIALS AND METHODS

2.1 | Study design and inclusion criteria

Electronic medical records of dogs and cats that were presented at University Veterinary Hospital of Bologna from 2010 to 2023 with a diagnosis of gastrointestinal occlusion or subocclusion were evaluated retrospectively.

To be included in the study, dogs and cats had to be occluded or suboccluded by the ingestion of at least one FB localized in the stomach/pylorus, duodenum and/or jejunum, and they had to have been treated surgically for the removal of the FB with LAER or with exploratory laparotomy and enterotomy. Presence of intestinal occlusion/subocclusion could be diagnosed by abdominal radiographs and/or ultrasound. Radiographically the evidence of radiopaque foreign material and/or the presence of markedly gas-dilated loops were considered suspected for occluding/suboccluding FBs. The presence and location of the FBs and the presence of intestinal partial or complete occlusion were determined by the ultrasonographic evidence

of dilation of the intestinal lumen orally to the FBs together with abnormal peristalsis of intestinal loop or pendulous movement of the ingesta inside the dilated bowel. Complete occlusion was suspected when no transit of material or gases was observed on ultrasound beyond the site of the FBs; while partial occlusion was suspected if some passage of fluid or gasses, even if reduced, was still present. Blood analyses (blood gas analysis, hematology, serum biochemistry) were performed to evaluate the systemic condition of the dogs and cats and evaluate possible comorbidities. The preoperative stabilization of the dogs and cats was evaluated by the attending clinician and occurred on a case-specific basis. Dogs and cats with other causes of gastrointestinal occlusion (i.e., neoplasm, volvulus, intussusception) were excluded from the study as were those with ultrasonographic signs of intestinal wall perforation, septic peritonitis was diagnosed, or those requiring enterectomy intraoperatively. All the dogs and cats in which the FBs or part of them were removed only by endoscopy without the need of a laparotomy, were excluded from the study.

All the dogs and cats meeting the inclusion criteria were enrolled and classified in one of the 2 groups: Group 1, when LAER was used to partially or completely remove the FB, or Group 2, when an exploratory laparotomy with enterotomy was performed.

Group 1 included all the dogs and cats with ultrasonographic evidence of FB localized in stomach and pylorus and/or duodenum/jejunum in which the LAER was applied or attempted. Group 2 included all the dogs and cats in which an exploratory laparotomy and consequently at least one enterotomy was performed without any LAER attempts. The choice to perform one of the two techniques was due to the preference of the surgeon, the localization of the FB and the availability of personnel for the intraoperative endoscopy.

The following data were recorded for each case meeting the inclusion criteria (both Groups 1 and 2): species, breed, sex, age, and type and characteristics of the FBs (sharp or blunt; discrete or linear; single or multiple), localization of the FBs (stomach/pylorus, and/or duodenum, and/or jejunum), presence and length of time of the clinical signs before surgery, and intraoperative and postoperative short-term complications (occurring within 14 days from surgery). The intraoperative and short-term complications were classified according to the Veterinary Cooperative Oncology Group—Common Terminology Criteria for Adverse Events (VCOG-CTCAE v2) with a grading system ranging from 1 to 5.¹⁴

Postoperative recovery was assessed in terms of length of time of postoperative analgesia administration, time for resumption of spontaneous feeding, and length of hospital stay.

The first part of the study assessed Group 1, specifically, the effectiveness of the LAER technique to partially or completely remove FBs, possible related factors, and the need and reason for surgical conversion to enterotomy or gastrotomy.

Group 1 (LAER) was further divided in subgroups according to the results of the LAER technique:

- A. Completely effective technique. Complete removal of single or multiple FBs using only LAER: when no intestinal or gastric incisions were required to remove the FB.
- B. Partially effective technique. Removal of one or more of multiple FBs or part of one FB with LAER but performing at least one intestinal incision: when one or more enterotomy was needed either to release the FB (as in the case of linear FBs) or if there were multiple FBs, and one or some of them needed an enterotomy in order to be removed.
- C. Necessity of conversion: when LAER was attempted but was impossible to be performed.

The factors considered for the effectiveness of the technique for the complete or partial removal of FBs or for the need of surgical conversion were: signalment of the dogs and cats, characteristics and localization of the FBs, presence and length of time of the clinical signs, imaging signs of occlusion, intraoperative findings of intestinal wall damage without gross signs of ischemic injury such as to require enterectomy, and the experience of the endoscopist.

The second part of the study was focused on comparing Groups 1 and 2 in terms of length of hospital stay, time of postoperative analgesia, time for resumption of postoperative spontaneous feeding, short-term complications, and the presence of postoperative ileus. Postoperative ileus was determined for both groups by the ultrasonographic evidence of delayed or absent gastrointestinal emptying combined with clinical signs of anorexia or vomiting.¹⁵

2.2 | Surgical technique and perioperative management

As the animals were considered stable to undergo anesthesia, they were premedicated with methadone (0.1–0.3 mg/kg IM), fentanyl (2 mcg/kg IM) or butorphanol (0.3 mg/kg IM) alone or in combination with dexmedetomidine (1–10 mg/kg) or ketamine (5–10 mg/kg IM) on a case-by-case basis at the discretion of the attending anesthesiologist. Fifteen minutes after premedication, if not already inserted, an intravenous catheter into the cephalic vein was placed. General anesthesia was induced with propofol

(2–6 mg/kg IV) or alfaxalone (1–3 mg/kg IV) and titrated to effect in order to achieve endotracheal intubation. General anesthesia was maintained with isoflurane in 100% oxygen delivered through a rebreathing system or with total intravenous anesthesia with propofol (0.1–0.4 mg/kg/min IV). Analgesia was maintained intraoperatively with fentanyl (5 mcg/kg/h), lidocaine (30–50 mcg/kg/min, in dogs) or a combination of both, if necessary.

A prophylactic dose of ampicillin-sulbactam (20 mg/kg IV) or cefazolin (22 mg/kg IV) was administered 30 min before the skin incision and repeated every 90 min until the end of the surgery.

The analgesic therapy used in the postoperative period included mainly opioids like methadone (0.1–0.2 mg/kg IV or IM) or buprenorphine (15–10 mcg/kg IV or IM). In all cases the dog or cat was assessed at the decline of the analgesic therapy by a surgeon or by other clinicians to evaluate the analgesic needs. All the dogs and cats were discharged when they were able to eat spontaneously and did not need parenteral analgesic therapy.

Postoperative gastrointestinal protectants (esomeprazole 0.7–1 mg/kg IV twice daily), antiemetics (maropitant 1 mg/kg IV once daily), and prokinetics (metoclopramide 0.2–0.5 mg/kg every 8 h subcutaneously) and enteral nutrition by nasoesophageal/nasogastric feeding tubes were administered on a clinical basis at discretion of the attendant clinician and surgeon.

Postoperative antimicrobials were not routinely administered, except in the case of major intraoperative contamination from the gastrointestinal tract, or evidence of postoperative infectious complications such as surgical site infection.

2.3 | Technique Group 1: LAER for removal of FBs

Flexible endoscopes (Pentax EG290kP and EG1840) were set up in the operating room. The dogs and cats were clipped before the procedure, placed in dorsal recumbency and the skin was then aseptically prepared.

For all the dogs and cats in which the FB was in the duodenum or in the jejunum, the procedure started with a celiotomy in order to assess the possibility of moving the FB into the stomach; if possible, then this was followed by endoscopic removal.

Briefly, once the celiotomy was performed, the abdominal cavity and the gastrointestinal tract were completely explored, and the loop with the FB was isolated. Laparotomy-assisted endoscopic removal was excluded if there were any signs of intestinal nonviability were present orally to the FB or at the level of the loop involved (i.e., if there was intestinal necrosis, or if ischemic

injury was suspected due to the color, thickness, and absence of blood vessel pulsation and peristalsis, or intestinal perforation); enterectomy and anastomosis were then performed and the dog or cat was excluded from the study. If the FB was movable orally, a manual taxis was gently applied to move the FB to the stomach or into the descending duodenum. Once the FB was pushed into the stomach, or into the descending duodenum, it was removed under endoscopic visualization using endoscopic forceps (i.e., alligator forceps, basket forceps); in some cases, the FB was gently manipulated through the gastric or intestinal wall until it was placed near the endoscopic forceps to allow it to be grasped and removed. If needed, endoscopic retrieval was aided by the surgeon's gentle and careful manipulation of the stomach or duodenum.

Once the FB was removed, the esophagus, stomach, and duodenum were explored by the endoscope, carefully avoiding overinflating the tract, and the remainder of the gastrointestinal tract was explored surgically to check for any additional FBs, any other possible mucosal or serosal tears, or signs of intestinal wall necrosis. The abdominal cavity was then closed routinely.

In all cases in which LAER was not feasible or completed successfully, a traditional enterotomy or gastrotomy was performed. Briefly, the bowel loop with the FB was isolated, a second surgical field was arranged, and intraluminal content was gently moved away, with gentle digital compression exerted orally and aborally to avoid intraoperative contamination. A longitudinal incision was made on the antimesenteric border of the bowel, immediately aboral to the FB and possibly distant from wall congestion areas, while aspirating eventual intestinal content; the FB was grasped with forceps (e.g., Allis forceps) and slowly pulled out, while gently pushing it from the opposite side. Tearing of the tissue was prevented by adequately extending the enterotomy, if necessary. Once removal was completed and no further material was found intraluminally, the enterotomy was closed with a single-layer, full-thickness, simple-interrupted suture pattern with 3–0 or 4–0 USP monofilament absorbable suture; leak testing and/or apposition of omentum were performed at surgeon's discretion, if deemed necessary. When a gastrotomy was required to removed FBs, the stomach was isolated and a second surgical field was arranged with laparotomy gauzes. Two stay sutures were placed at the ventral aspect of the gastric body, midway between the greater and the lesser curvature, and a longitudinal full-thickness incision was made between them. The FB was identified visually and/or through stomach palpation, then grasped with forceps and slowly pulled out. When removal was complete, the gastrotomy was closed in a two-layers suture pattern: a simple continuous pattern for the gastric mucosa and submucosa and an inverting pattern for the tunica muscularis

and the tunica serosa. In both cases, celiotomy was routinely closed.

2.4 | Group 2: exploratory laparotomy, and enterotomy

The dogs included in Group 2 underwent ventral midline celiotomy, and exploration of the abdominal cavity. The affected portion of the bowel and/or stomach were isolated and judged to be vital. Enterotomy or gastrotomy for FB removal were performed as described for Group 1.

2.5 | Statistical analysis

The data were assessed for normality using the Shapiro-Wilk test and were expressed as mean and standard deviation, or median and range (minimum and maximum), based on normality distribution. The χ^2 test was used to compare the differences in the categorical variables for Group 1 (e.g., signalment parameters such as species and sex, characteristics and localization of the FBs, presence/absence of clinical signs, presence/absence of occlusion, intraoperative findings of intestinal wall damage without ischemic injury, experience of the endoscopist) between subgroups A, B, C, or between A (complete removal of all the FBs with only LAER) versus B and C, or between C (necessity of conversion) vs. A and B. The χ^2 test was used to compare Groups 1 and 2 in terms of intraoperative and postoperative complications, and the presence of postoperative ileus. The Mann-Whitney *U*-test was used to compare the continuous dependent variables (age, weight, length of time of the clinical signs, length of time of postoperative analgesia, time for resumption of spontaneous feeding, and length of hospital stay) and the independent categorical data (Groups 1 and 2; complete removal of all the FBs with only LAER – A vs. B and C; necessity of conversion – C vs. A and B). The Kruskal-Wallis test was used to compare the continuous dependent variables (age, weight, length of time of the clinical signs) between the subgroups A, B and C. Statistical significance was $p < .05$. The calculations were completed using MedCalc Statistical Software version 19.2.6 (MedCalc, Software bv Ostend, Belgium; <https://www.medcalc.org>; 2020).

3 | RESULTS

One hundred and eighty one cases were enrolled in the study. Sixteen/181 cases were excluded because of intraoperative findings of a nonviable intestinal wall, requiring enterectomy and anastomosis, and 84/181 cases were

excluded as the FBs were removed with the endoscope alone. Thus, 81 animals were finally enrolled.

Forty of 81 cases (26 dogs and 14 cats) were enrolled in Group 1 (LAER). There were 13 male (two neutered) and 13 female (eight spayed) dogs, and seven male (four neutered) and seven female (four spayed) cats. Forty-one of 81 cases (34 dogs and seven cats) were enrolled in Group 2 (exploratory laparotomy and enterotomy). These were 25 male (four neutered) and nine female (five spayed) dogs, and five male (three neutered) and two female (spayed) cats. The dog breeds involved in Group 1 were Labrador ($n = 3$), English setter ($n = 3$), dachshund ($n = 3$), mixed breeds ($n = 2$), boxer ($n = 2$), and one of each of the following breeds: German shepherd, American Staffordshire Terrier, French bulldog, Hungarian hound, English bull terrier, Cavalier King Charles spaniel, Bernese mountain dog, Doberman, epagneul Breton, cane Corso, rottweiler, Samoyed, and Yorkshire terrier. The dog breeds involved in Group 2 were mixed breeds ($n = 3$), dachshund ($n = 3$), Labrador retriever ($n = 3$), Romagna water dog ($n = 3$), pitbull ($n = 3$), American Staffordshire terrier ($n = 2$), Italian hound ($n = 2$), French bulldog ($n = 2$), cocker spaniel ($n = 2$), Doberman ($n = 2$), German shepherd ($n = 2$), and one of each of the following breeds: poodle, Bernese mountain dog, epagneul Breton, Cavalier King Charles spaniel, Jack Russell terrier, pointer and Rhodesian ridgeback. The median age of the dogs in Group 1 was 51 months (range: 6–141 months) and the median weight was 18.6 kg (range: 2.8–57 kg), and the median age of the dogs in Group 2 was 65 months (range: 4–167 months), and the median weight was 19.1 kg (range: 6–51 kg). There were 13 domestic short-hair cats and one Siberian cat enrolled in Group 1. The median age of these cats was 27 months (range: 4–96 months), and the median weight was 4.5 kg (range: 1.6–5.6 kg). In Group 2 there were 5 domestic short-hair cats, one Siberian cat and one sacred cat of Burma. The median age of these was 6 years (range 7 months–12 years and 7 months), and the median weight was 3.9 kg (range: 3–5 kg).

Clinical signs were reported in 32/40 cases in Group 1, but in 8/40 cases, these data were missing. Two out of 32 of the dogs and cats in which clinical signs were reported were asymptomatic, but in the remaining 30, the symptoms had appeared in a median of 24 h (12 h–14 days) before surgery. The clinical signs were mainly consistent with vomiting in 30/30 of the symptomatic cases, associated with anorexia/dysorexia in 20/30 or with diarrhea in 2/30 cases. In Group 2 clinical signs were reported with a median length of 48 h (range: 12 h–30 days).

The types of FBs are reported in Table 1. In Group 1, 31/40 FBs were classified as blunt, and 9/40 as sharp; 27/40 FBs were single and 13/40 were multiple; 25/40

TABLE 1 Type of foreign bodies.

	Group 1	Group 2
Plastic/rubber	<i>n</i> = 3	<i>n</i> = 15
Tissue/cloths	<i>n</i> = 9	<i>n</i> = 6
Wire	<i>n</i> = 10	<i>n</i> = 1
Trichobezoar	<i>n</i> = 2	<i>n</i> = 4
Rope	<i>n</i> = 6	<i>n</i> = 0
Nuts	<i>n</i> = 1	<i>n</i> = 7
Bone	<i>n</i> = 0	<i>n</i> = 2
Stone	<i>n</i> = 0	<i>n</i> = 1
Cork	<i>n</i> = 1	<i>n</i> = 0
Mixed FBs	<i>n</i> = 8	<i>n</i> = 3
Material not reported	<i>n</i> = 0	<i>n</i> = 2

Note: Details reported regarding the type of foreign bodies in Groups 1 and 2.

were linear FBs, and 15/40 were discrete. In 29 of the 39 dogs and cats of Group 2 in which the type (material) of the FB was reported, the FBs were classified as blunt, while in 10/39, they were classified as sharp FBs. Six were linear and 35 were discrete FBs; 37 cases had a single FB and four had multiple FBs.

The main localization of the FBs in Group 1 was the gastro-jejunal (24/40), followed by the duodenum (6/40), the jejunum (6/40), and the gastro-duodenum (4/40). Complete intestinal occlusion was confirmed during surgery in 25 out of the 36 dogs and cats of Group 1 in which these data were available, while intestinal wall damage was intraoperatively reported in 18/37 dogs and cats because in 3/40 cases these data were missing.

Information regarding intraoperative and postoperative complications was available for 39/40 dogs and cats in Group 1. An intraoperative complication was reported in 1/39 dogs and cats in Group 1, consistent with a dog presenting two serosal tears towards the antimesenteric side due to a linear FB, discovered after enterotomy and subsequent resolution of the intestinal plication, and a suture reinforcement was applied (grade 2 complication). None of the dogs and cats in Group 2 experienced intraoperative complications.

Short-term postoperative complications were reported in 13/40 dogs and cats in Group 1: 10/40 dogs and cats developed postoperative ileus (2/10 grade 1, 7/10 grade 2, 1/10 grade 3); 2/40 developed superficial surgical site infection (SSI, grade 1) and one dog developed pancreatitis (grade 2). In Group 2, 16/41 dogs and cats developed 18 short-term postoperative complications, with 3/16 dogs and cats developing multiple postoperative complications. Overall, 12/41 dogs and cats developed postoperative ileus (2/12 grade

1, 9/12 grade 2, 1/12 grade 3), 2/41 dogs and cats developed grade 3 aspiration pneumonia, and one of each complication was reported: grade 2 superficial surgical site dehiscence, grade 2 myocardial injury, and grade 1 SSI. Finally, one dog developed postoperative persistence of a gastric FB, which required gastroscopy the day after surgery for its retrieval (grade 4). SSI was suspected in case of local (i.e., wound swelling or discharge) and/or systemic (i.e., fever) clinical signs of infection and confirmed by cytology and culture and sensitivity testing; pancreatitis was suspected in case of abdominal pain or anorexia, high levels of pancreatic-specific lipase and US indirect signs (i.e., hyperechoic peripancreatic fat or reactivity). Myocardial injury was suspected with electrocardiographic evidence of premature ventricular complexes and confirmed by high levels of serum troponin I. A nasogastric tube was applied for postoperative food intake management after at least 48 h of fasting or in case of ileus in a dog and in a cat in Group 1 (subgroup A) (2/40) and in three dogs in Group 2 (3/41).

The results concerning the length of time of the postoperative analgesic therapy, resumption of spontaneous feeding, and length of hospital stay are summarized in Table 2.

3.1 | Laparotomy-assisted endoscopic removal

In 35/40 cases, the LAER was considered completely or partially effective in removing the FBs. Subgroup A included 18 cases (18/40), and the LAER was performed without any gastric or intestinal incision. Subgroup B included 17 cases (17/40), and at least one enterotomy was required.

In particular, in 10/17 cases of subgroup B one enterotomy was required to release the most caudal part of the occlusive FB (which was not movable) from the intestinal wall, permitting the LAER for the remaining part. Of these, 10 had linear FBs and 2/10 also had multiple FBs connected to each other.

In the remaining 7/17 cases of subgroup B, in which the LAER allowed the retrieval of at least one of the multiple FBs, one or more enterotomies were needed to remove the FBs as they were anchored in distant parts of the small intestine (one enterotomy in 6/7 cases; 4 enterotomies in 1/7 cases).

In 5/40 cases (subgroup C), conversion to enterotomy (3/5 cases), gastrotomy (1/5), or gastrotomy and enterotomy (1/5) was required due to the presence of nonmovable FBs in 4/5 cases and intestinal wall damage in 3/5 cases, inability to grasp the FB with the endoscope in 1/5

TABLE 2 Postoperative recovery data for groups 1 and 2.

	Group 1			Group 2			<i>p</i>
	Median	Minimum	Maximum	Median	Minimum	Maximum	
Length of postoperative hospital stay (h)	48	0	288	72	48	96	.006*
Postoperative analgesia (h)	36	0	192	48	24	120	.0001*
Resumption of spontaneous feeding (h)	24	0	240	36	24	108	.012*

Note: Assessment of postoperative recovery in Group 1 and 2. The *p* values are reported for statistical differences between the two groups.

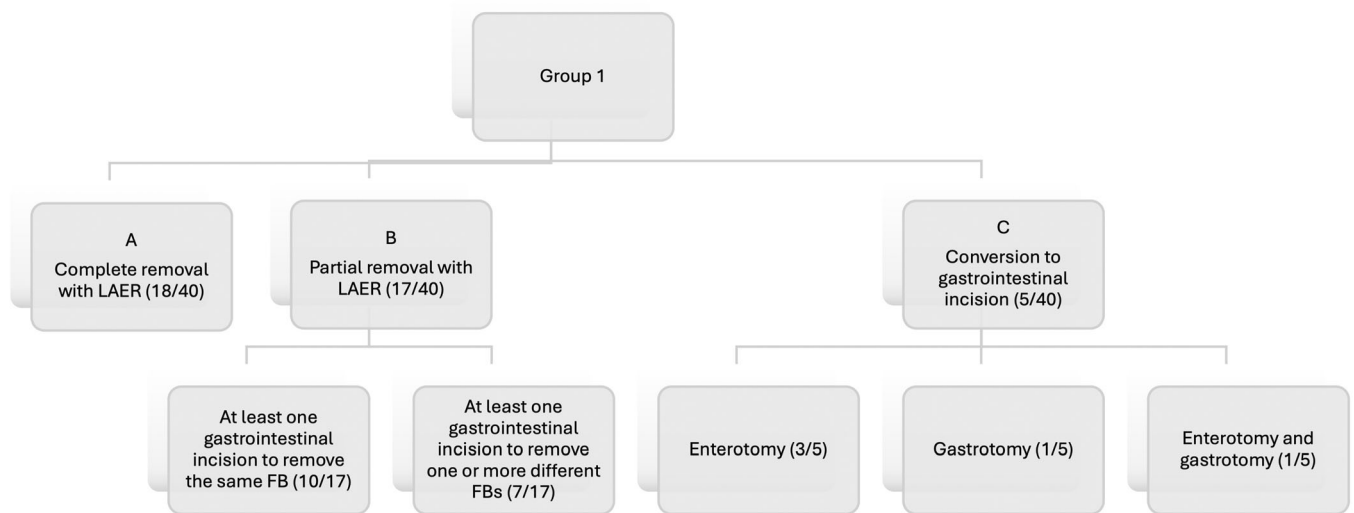


FIGURE 1 Summary of the results related to the effectiveness of the laparotomy-assisted endoscopic removal of foreign bodies in Group 1.

	A versus B + C	C versus A + B	A versus B versus C
Sharp and blunt FB	<i>p</i> = .675	<i>p</i> = .115	<i>p</i> = .099
Single and multiple FB	<i>p</i> = .110	<i>p</i> = .898	<i>p</i> = .059
Linear and discrete FB	<i>p</i> = .869	<i>p</i> = .537	<i>p</i> = .456
Localization	<i>p</i> = .120	<i>p</i> = .330	<i>p</i> = .178
Intestinal wall damage	<i>p</i> = .043*	<i>p</i> = .235	<i>p</i> = .111

Note: Statistical analysis of the variables considered, and the *p* values reported for Group 1. The complete effectiveness (removal of all the foreign bodies) of the laparotomy-assisted endoscopic removal is expressed by comparing subgroup A versus both subgroups B and C; the need to convert to traditional enterotomy is expressed by comparing subgroup C versus both subgroups A and B; the difference between the 3 subgroups (A, B, C) is reported in column A versus B versus C.

TABLE 3 Foreign bodies characteristics and intraoperative findings for Group 1.

cases, and numerous adhesions from prior surgeries for FB removal in 1/5 cases (Figure 1).

3.2 | Statistical results

In Group 1, the effectiveness of the LAER technique for complete or partial (with at least one intestinal incision needed) removal of FBs and the necessity of converting to enterotomy were not affected by species, sex, age, or

weight, of the dogs and cats, characteristics or localization of the FBs. No differences were observed between the same variables in the subgroups A, B, C when considered individually (Table 3).

The presence and length of the clinical signs, and the presence of intestinal occlusion did not affect the effectiveness of the technique for complete removal of all FBs (A vs. B and C) or the need for conversion (C vs. A and B), nor did the experience of the clinician performing the endoscopy.

TABLE 4 Postoperative recovery data for subgroups of Group 1.

	Subgroup A			Subgroup B + C			<i>p</i>
	Median	Minimum	Maximum	Median	Minimum	Maximum	
Length of postoperative hospital stay	24	0	288	72	0	144	.003*
Postoperative analgesia	12	0	192	48	24	96	.002*
Resumption of spontaneous feeding	18	0	240	30	12	72	.048*

Note: The assessment of postoperative recovery in Group 1. The comparison is between subgroup A in which the laparotomy-assisted endoscopic removal was completely effective without any gastrointestinal incision, and the subgroups B and C in which at least one gastrointestinal incision was required. The *p* values are reported for the statistical differences between subgroup A versus subgroups B and C.

In Group 1, in the dogs and cats with intestinal wall damage, the LAER (A and B compared with C) did not affect the development of short-term postoperative complications ($p = .234$). However, the intraoperative findings of intestinal wall damage were associated with the need for at least one surgical incision involving the gastrointestinal tract (A vs. B and C) ($p = .043$) (Table 3). Furthermore, in Group 1, when comparing subgroup A with subgroups B and C, no differences were noted in terms of postoperative short-term complications ($p = .657$) or the presence of postoperative ileus ($p = .323$).

In Group 1, the dogs and cats in which LAER was effective for the removal of all the FBs (subgroup A) had a shorter postoperative length of hospital stay ($p = .003$), less need for analgesia ($p = .002$), and a shorter resumption time to spontaneous feeding ($p = .048$) when compared with dogs and cats in which at least one intestinal incision (subgroups B and C) was performed, as reported in Table 4.

The same differences also appeared when comparing all the dogs and cats in Group 1 with those in Group 2. There was a shorter postoperative length of hospital stay, less need for analgesia, and a shorter resumption time to spontaneous feeding in Group 1, as is reported in Table 2.

Finally, when comparing Groups 1 and 2, no differences were noted in terms of age ($p = .055$), weight ($p = .230$), intraoperative complications ($p = .349$), postoperative short-term complications ($p = .602$), and the presence of postoperative ileus ($p = .590$).

4 | DISCUSSION

This study retrospectively compared the outcomes of the LAER technique, recently reported by Demars et al., with the traditional approach for the retrieval of gastrointestinal FBs, confirming the hypothesis that the LAER technique of FBs improved the postoperative recovery. A reduced need for analgesia, a shorter length of hospital stay, and an earlier resumption of spontaneous feeding were observed in

cases in which the LAER technique was partially or completely effective, when compared with cases in which traditional gastrointestinal surgery was performed.

Early enteral nutrition in critically ill dogs and cats, especially after gastrointestinal surgery, has beneficial physiological effects, reducing oxidative stress, decreasing the incidence of ileus and bacterial translocation, increasing wound healing and, more generally, improving outcomes.^{16–19} The LAER technique may be associated with an early resumption of spontaneous enteral feeding. Although enteral nutrition could be ensured through feeding tubes (e.g., nasoesophageal or nasogastric tubes), spontaneous food intake is commonly preferred because of its positive effects on postoperative recovery.²⁰ In this study, nasogastric tubes were used with a small number of dogs and cats in both groups. It is unlikely that they had an impact on earlier resumption of spontaneous feeding, as they were applied after at least 48 h of fasting, which is a longer time compared to the medians reported in the two groups (median 24 h in Group 1 and 36 h in Group 2).

Unlike what was expected, but similar to what has already been reported,⁹ the LAER technique did not result in a lower incidence of postoperative complications, specifically postoperative ileus, when compared with dogs and cats who only underwent enterotomy. This result may be explained by the fact that the pathogenesis of postoperative ileus is multifactorial, and anesthesia, opioids, and manipulation of the gastrointestinal tract contribute to its development, even if the gastrointestinal tract has not been incised.^{15,21,22} However, the LAER technique resulted in a low incidence of major postoperative complications (grades 3 and 4 of the VCOG-CTCAE grading system),¹⁴ reported in only one dog in Group 1, but they did develop in four dogs and cats in Group 2. Of these, one dog developed a grade four complication, consisting of the persistence of a gastric FB in the stomach in the postoperative period, which required a second general anesthesia and a gastroscopy to be removed. This complication would have been avoided had the LAER technique been used.

None of the dogs and cats in either of the two groups experienced septic peritonitis in the postoperative period. Whenever the gastrointestinal tract is incised, there is a potential risk of wound dehiscence (especially in case of hypoproteinemia, ileus, and enteric dismicrobism).^{12,18,23–25} This could lead to septic peritonitis, the incidence of which after enterotomy reported varies from 2 to 12% and can be fatal in the majority of cases.^{11,12,18,23–25} No cases of dehiscence were documented in Group 2 in this study. However, even if the risk of dehiscence is avoided when using the LAER technique, the presence of intestinal wall damage, even without clear evidence of ischemic injury, could potentially lead to necrosis and intestinal perforation.

The same technique has recently been described by Demars et al., where they observed a higher conversion rate, 33/58, due to failure of the technique, in comparison to this study where complete failure was reported in 5/40.⁹ The differences in our results are most likely due to differences in inclusion criteria. In the previous study, the LAER technique was used for any case of FB obstruction regardless of localization.⁹ In the current study, we employed the LAER technique for patients with proximal FBs, linear FBs with pyloric anchorage, and for cases where we felt a laparotomy and digital manipulation of the intestine would help endoscopic removal.

It can be speculated that the LAER technique might require longer time in comparison with traditional enterotomy, although Demars et al. reported the opposite. These results could be related to the operator's experience and learning curve, as reported for other minimally invasive techniques.^{9,26} Once the technique has been learned, the surgical time may be shortened and this could be particularly beneficial in unstable cases, where there is a substantially higher risk of postenterotomy complications.^{9,12,25} Unfortunately, the surgical times were not available in medical records for most of the dogs and cats included in the current study; these data could not therefore be compared.

Considering the factors which could affect the efficacy of the LAER in the present study, none of the aspects related to the signalment of the dogs and cats was statistically associated with the effectiveness of the LAER technique for the complete or partial removal of one or multiple FBs or to the necessity of conversion. However, it is interesting to note that none of the cats required surgical conversion: there were 9/14 cats in which LAER was effective (subgroup A) and 5/14 in which LAER was associated with at most one gastrointestinal incision (subgroup B). These data should be interpreted with caution as they probably reflect the low number of cats in the study combined with the low number of LAER failures as opposed to a truly better outcome in cats.

Considering the characteristics and the localization of the FBs neither of the aforementioned were found to affect the effectiveness of the LAER for the complete or partial removal of one or multiple FBs or the need for conversion. This study therefore did not identify specific characteristics or localizations between stomach/pylorus, duodenum and/or jejunum, which would discourage the use of LAER. It was hypothesized that it would be more difficult to remove sharp FBs using LAER because, due to their shape, moving them back into the stomach could increase inflammation or tears in an already damaged gastrointestinal tract; in fact, 6/9 sharp FBs required at least one gastrotomy or enterotomy versus 15/31 of the blunt FBs; however, these results were not statistically significant ($p=.099$) and non-significant complications were reported for these cases.

Even if one of the potential risks of this technique was that of inducing additional irritation of an already damaged gastrointestinal tract, the dogs and cats with intraoperative findings of intestinal wall damage which were treated with LAER did not have more postoperative complications when compared with the others in the study; however, this was associated with a need to perform at least one enterotomy ($p = .043$).

The effectiveness of the technique for the complete or partial (with at least one intestinal incision needed) removal of one or multiple FBs was not affected by linear FBs which represented 25/40 of the FBs considered. They were easily removed using LAER because, while the surgeon moved the FB to the stomach, the endoscopist could grasp and withdraw the FB from the stomach, thus reducing the intraoperative time. Furthermore, in the case of linear FBs that could not be moved using the LAER alone, the most caudal part of the nonmovable FB was removed by means of an enterotomy, and the remaining FB was frequently able to be retrieved using the endoscope, thus avoiding another proximal incision. In the case of multiple FBs, fixed in distant parts of the small intestine, some of them were able to be removed using LAER thereby reducing the risk of multiple incisions, resulting in less invasive surgery and time required for the procedure, as already reported.^{5,9} Furthermore, once the FB is back in the stomach, even if the endoscopic removal of the FB fails, a gastrotomy, as compared with an enterotomy, could lead to fewer complications and a lower risk of dehiscence, especially in a damaged intestine.^{25,27} Due to the retrospective nature of the study, in cases of partial removal of FBs (Group 1, subgroup B) it was not possible to determine whether LAER objectively reduced the number of gastrointestinal incisions, especially when dealing with linear or multiple FBs, or if all the FBs could have been removed from the same enterotomy.

Additional factors that have not influenced the effectiveness of the technique for the complete or partial

removal of one or multiple FBs are the presence and length of time of the clinical sign and the presence of intestinal occlusion. In human medicine, there is evidence that the period of time between FB ingestion and the time of the treatment is an important risk factor regarding conversion from endoscopy to surgery; however, the same concept cannot be directly applied to veterinary medicine because the moment of ingestion of the FB is rarely known, and the onset of the symptoms may be delayed and not always noted.¹⁰

The experience of the clinician who performed the endoscopy did not affect the outcome. These data confirmed that the procedure is easy and can be performed even by an inexperienced operator. In the case of difficulty in grasping the FB, the endoscopist may benefit from the aid of a surgeon who is able to direct the FB towards them. This procedure is easy and offers the advantages of a clean over a clean-contaminated procedure, avoiding the risk of intraoperative abdominal contamination and reducing the risk of postoperative wound dehiscence and septic peritonitis.^{8–10}

The disadvantages of the technique are that specialized equipment, such as an endoscope, are required and that, in addition to the surgeons, the presence of another operator, who deals only with the endoscope, is necessary during surgery.

The main limitations of this study are related to its retrospective nature, and this means that the protocols were not standardized and the distribution of the dogs and cats to the two groups was not randomized. Several data were missing and could not be evaluated as for example the time of anesthesia and surgery, or pain grading scale used; thus, the tapering of analgesic therapy was not standardized or could be influenced by subjective evaluation. Due to the retrospective nature, it was not possible to compare the overall hospital costs for LAER and enterotomy, but LAER could presumably be about equal, avoiding costs related to the enterotomy and further reducing postoperative hospital stay. Nevertheless, it is known that other minimally invasive procedures present inherent higher costs due to specialized instruments or personnel, and sometimes longer procedure times, especially in learning settings, in favor of a lower morbidity, thus this concern should be further investigated.

Another important limitation of the study is related to the low number of dogs and cats included in both groups and of complete failures of the technique, which made it difficult to identify the factors that could have influenced the outcome.

In conclusion, the LAER technique was effective in resolving intestinal occlusion or subocclusion by removing a variety of FBs (including irregularly shaped objects) or part of them and so reducing the number of gastrointestinal

incisions required. The technique was also useful in removing FBs in areas difficult to reach endoscopically, such as the duodenum and the jejunum. The LAER technique may lead to a faster postoperative recovery when compared with an enterotomy; however, it did not decrease the incidence of postoperative complications, even if they were mostly minor. Further studies are needed to evaluate whether the time required to complete the procedure and the cost are comparable with the traditional technique.

ACKNOWLEDGMENTS

Author Contributions: Cola V, DVM: Manuscript preparation, study design, data assessment, statistical analysis. Ferrari C, DVM: Manuscript preparation, study design, data collection, statistical analysis. Del Magno S, DVM, PhD, DECVS (Small Animal): Project design, data assessment, manuscript review. Foglia A, DVM, PhD: Project design, data assessment, manuscript review. Zanardi S, DVM: Project design, data assessment, manuscript review. Ciammaichella L, DVM: Project design, data assessment, manuscript review. Capitani O, DVM: Study design, data assessment, manuscript review. Pietra M, DVM, PhD: Study design, data collection, statistical analysis, manuscript review. Pisoni L, DVM, PhD: Study design, data collection, statistical analysis, manuscript review.

CONFLICT OF INTEREST

The authors declare no conflicts of interest related to this paper.

ETHICS STATEMENT

No ethical approval was necessary for this retrospective study; while a written informed consent was signed by the owner for the surgical and anesthesiologic procedure for each animal.

ORCID

Veronica Cola  <https://orcid.org/0000-0002-8771-1125>

Sara Del Magno  <https://orcid.org/0000-0002-2900-6989>

REFERENCES

1. Gianella P, Pfammatter NS, Burgener IA. Oesophageal and gastric endoscopic foreign body removal: complications and follow-up of 102 dogs. *J Small Anim Pract.* 2009;50:649-654.
2. Hayes G. Gastrointestinal foreign bodies in dogs and cats: a retrospective study of 208 cases. *J Small Anim Pract.* 2009;50:576-583.
3. Schwartz Z, Coolman BR. Disposable skin staplers for closure of linear gastrointestinal incisions in dogs. *Vet Surg.* 2018;47(2):285-292.
4. Mishra NK, Appert HE, Howard JM. The effects of distention and obstruction on the accumulation of fluid in the lumen of small bowel of dogs. *Ann Surg.* 1974;180(5):791-795.
5. Maxwell EA, Dugat DR, Waltenburg M, et al. Outcomes of dogs undergoing immediate or delayed surgical treatment for

- gastrointestinal foreign body obstruction: a retrospective study by the Society of Veterinary Soft Tissue Surgery. *Vet Surg*. 2021;50:177-185.
6. Šmit I, Crnogaj M, Brkljačić M, et al. Endoscopic removal of esophageal and gastric foreign bodies in dogs: the prevalence, risk factors and efficacy of removal. *Vet Arh*. 2018;88:481-496.
 7. Di Palma C, Pasolini MP, Navas L, et al. Endoscopic and surgical removal of gastrointestinal foreign bodies in dogs: an analysis of 72 cases. *Animals*. 2022;12:1376.
 8. Power AM, Diamond DW, Puetthoff C. Laparotomy-assisted transoral foreign body retrieval in small animals: 10 cases (2018-2020). *Top Companion Anim Med*. 2021;42:100504.
 9. Demars C, Boland L, Minier K. Surgical removal of intestinal foreign bodies using a laparotomy-assisted endoscopic approach in dogs and cats and comparison with enterotomy. *J Small Anim Pract*. 2023;64:43-50.
 10. Lee HJ, Kim HS, Jeon J, et al. Endoscopic foreign body removal in the upper gastrointestinal tract: risk factors predicting conversion to surgery. *Surg Endosc*. 2016;30:106-113.
 11. Shales CJ, Warren J, Anderson DM, Baines SJ, White RA. Complications following full-thickness small intestinal biopsy in 66 dogs: a retrospective study. *J Small Anim Pract*. 2005;46(7):317-321.
 12. Strelchik A, Coleman MC, Scharf VF, Stoneburner RM, Thieman Mankin KM. Intestinal incisional dehiscence rate following enterotomy for foreign body removal in 247 dogs. *J Am Vet Med Assoc*. 2019;255:695-699.
 13. Lopez DJ, Holm SA, Korten B, Baum JI, Flanders JA, Sumner JP. Comparison of patient outcomes following enterotomy versus intestinal resection and anastomosis for treatment of intestinal foreign bodies in dogs. *J Am Vet Med Assoc*. 2021;258(12):1378-1385.
 14. LeBlanc AK, Atherton M, Bentley RT, et al. Veterinary cooperative oncology group—common terminology criteria for adverse events (VCOG-CTCAE v2) following investigational therapy in dogs and cats. *Vet Comp Oncol*. 2021;19(2):311-352.
 15. Husnik R, Gaschen F. Gastric motility disorders in dogs and cats. *Vet Clin North Am Small Anim Pract*. 2021;51:43-59.
 16. McClave SA, Heyland DK. The physiologic response and associated clinical benefits from provision of early enteral nutrition. *Nutr Clin Pract*. 2009;24:305-315.
 17. Lewis SJ, Andersen HK, Thomas S. Early enteral nutrition within 24 h of intestinal surgery versus later commencement of feeding: a systematic review and meta-analysis. *J Gastrointest Surg*. 2009;13:569-575.
 18. Ellison GW. Complications of gastrointestinal surgery in companion animals. *Vet Clin North Am Small Anim Pract*. 2011;41:915-934.
 19. Hoffberg JE, Koenigshof A. Evaluation of the safety of early compared to late enteral nutrition in canine septic peritonitis. *J Am Anim Hosp Assoc*. 2017;53:90-95.
 20. Corbee RJ, Van Kerkhoven WJ. Nutritional support of dogs and cats after surgery or illness. *Open J Vet Med*. 2014;4:44-57.
 21. Whitehead K, Cortes Y, Eirmann L. Gastrointestinal dysmotility disorders in critically ill dogs and cats. *J Vet Emerg Crit Care*. 2016;26:234-253.
 22. Wattchow D, Heitmann P, Smolilo D, et al. Postoperative ileus—an ongoing conundrum. *Neurogastroenterol Motil*. 2021;33:e14046.
 23. Allen DA, Smeak DD, Schertel ER. Prevalence of small intestinal dehiscence and associated clinical factors: a retrospective study of 121 dogs. *J Am Anim Hosp Assoc*. 1992;28:70-76.
 24. Wylie KB, Hosgood G. Mortality and morbidity of small and large intestinal surgery in dogs and cats: 74 cases (1980-1992). *J Am Anim Hosp Assoc*. 1994;30:469-474.
 25. Grimes JA, Schmiedt CW, Cornell KK, Radlinsky MAG. Identification of risk factors for septic peritonitis and failure to survive following gastrointestinal surgery in dogs. *J Am Vet Med Assoc*. 2011;238:486-494.
 26. Barry SL. Intestinal incision dehiscence. *Clinician's Brief*. 2016;71-76.
 27. Case JB, Ellison G. Single incision laparoscopic-assisted intestinal surgery (SILAIS) in 7 dogs and 1 cat. *Vet Surg*. 2013;42:629-634.

How to cite this article: Cola V, Ferrari C, Del Magno S, et al. Laparotomy-assisted endoscopic removal of gastrointestinal foreign bodies: Evaluation of this technique and postoperative recovery in dogs and cats. *Veterinary Surgery*. 2024; 53(7):1266-1276. doi:[10.1111/vsu.14126](https://doi.org/10.1111/vsu.14126)