

## CASE REPORT

# Long-term outcome of permanent tracheostomy management in two brachycephalic dogs using a commercial and a three-dimensional-printed silicone stent

Janina N. Janssen DVM  | Gabriele M. Gradner DVM, DECVS |  
Lea Liehmann DVM, DECVS

Department for Small Animals and Horses, Small Animal Surgery, University of Veterinary Medicine Vienna, Vienna, Austria

## Correspondence

Gabriele M. Gradner, Department for Small Animals and Horses, University of Veterinary Medicine Vienna, Veterinärplatz 1, 1210 Vienna, Austria.  
Email: [gabriele.gradner@vetmeduni.ac.at](mailto:gabriele.gradner@vetmeduni.ac.at)

## Abstract

**Objective:** To report the long-term outcome of utilization of a silicone stent to support the management of a permanent tracheostomy.

**Study design:** Short case series.

**Animals:** Two client-owned brachycephalic dogs.

**Methods:** Two brachycephalic dogs with stage III laryngeal collapse underwent permanent tracheostomy. After the tracheostomy had healed, a silicone stent was inserted to support the stoma and facilitate home care. One dog wore a commercially available silicone stent for the follow-up period of 2 years. For the dog in Case 2, a 3D-printed, medical-grade silicone stent with an increased length was designed, as the dog had developed skin sores from the commercial device.

**Results:** Both dogs tolerated the silicone stent well. Stent care was managed by the owners without need for assistance. They reported that the silicone stent facilitated cleaning of the stoma surroundings and that they felt an increased confidence in airway patency, as the device prevented the tracheal stoma from collapsing. In Case 1, tracheoscopy 1 year after first stent insertion revealed minimal visible changes to the tracheal stoma. In Case 2, the 3D printed silicone stent led to a remission of skin sores and the dog wore the device comfortably until succumbing to an unrelated disease 13 months later.

**Conclusion:** The insertion of a silicone stent is a simple and cost-effective method to improve home care of dogs with permanent tracheostomy. Larger dogs, as in Case 2, may benefit from custom-designed 3D-printed stents.

## 1 | INTRODUCTION

**Abbreviations:** BOAS, brachycephalic obstructive airway syndrome; CT, computed tomography; ICU, intensive care unit; LC, laryngeal collapse; PT, permanent tracheostomy; TS, tracheal stent.

Permanent tracheostomy (PT) is a salvage procedure in cases of permanent upper airway impairment. In dogs with brachycephalic upper airway syndrome (BOAS), this

This is an open access article under the terms of the [Creative Commons Attribution](https://creativecommons.org/licenses/by/4.0/) License, which permits use, distribution and reproduction in any medium, provided the original work is properly cited.

© 2024 The Authors. *Veterinary Surgery* published by Wiley Periodicals LLC on behalf of American College of Veterinary Surgeons.

intervention is necessary when surgical possibilities have been exhausted or when anatomy and secondary changes such as laryngeal collapse (LC) lead to continuing respiratory distress.

LC develops over time, when the laryngeal cartilages are continuously exposed to negative pressure induced by inspiratory respiratory effort. Stage I LC is the mildest form and manifests as laryngeal sacculae eversion. With stage II disease, the cuneiform process of the arytenoid cartilage fatigues and becomes medially displaced with inspiration. Stage III results in collapse of the corniculate process and loss of the dorsal arch of the glottic rima, leading to severe inspiratory dyspnea.<sup>1</sup> To treat LC, all inciting causes must be addressed first, to reduce the negative inspiratory pressure.

In cases of severe LC, different surgical options have been proposed, including cricoarytenoid–thyroarytenoid lateralization, partial laryngectomy, or PT.<sup>2–4</sup> Recently, cuneiformectomy has been investigated in 87 dogs with stage II or III LC, undergoing multilevel BOAS surgery. The patients improved clinically and the procedure was not associated with a higher general complications rate, rendering this procedure a valuable option before taking the step of performing a PT as salvage procedure.<sup>5</sup> A pilot study reported promising outcomes after subtotal epiglottectomy and photoablation of unilateral arytenoid cartilage in brachycephalic dogs with stage III LC. When validated with a larger number of cases and long-term follow up, this technique could be an alternative to PT for this particular indication.<sup>6</sup>

Publications about long-term outcomes of PT are scarce and involve limited case numbers. Complication rates are high and range from 50% to 82.1%.<sup>7–9</sup> They most commonly include coughing, aspiration pneumonia, or occlusion of the stoma because of mucus, stenosis, collapse, or redundant skin folds.<sup>8</sup> Gobbetti et al. recently reported 15 cases of LC secondary to BOAS treated with PT and found that it was a valuable treatment option, with all long-term survivors having a markedly improved quality of life, as judged by the owners. However, they reported similarly high complication rates as previous studies.<sup>9</sup>

Management of a PT can be challenging for owners because mucus may occlude the stoma, or collapse of the opening may occur dependent on body position. However, mucus production decreases over time, thus management usually becomes easier for the owners. In a questionnaire reporting long-term outcome, 89.7% of owners were satisfied with the procedure.<sup>8</sup> Regarding our brachycephalic population, we encountered cases where obesity, presence of hypoplastic trachea, or excess skin in the neck region posed additional risks for the long-term care of a PT. We therefore looked for a means to facilitate care for these dogs.

Trinterud et al.<sup>10</sup> have reported that silicone tracheal stents (TS) are feasible and safe. Having been designed for stretching human earlobes, these silicone stents are available commercially in various sizes and are made of nontoxic silicone material. Their study included 18 dogs that underwent upper airway surgery and needed a temporary tracheostomy for postoperative care. The TS was inserted as an alternative to a conventional tracheostomy tube. The dogs tolerated the TS well, and the authors found cleaning and stoma care easier than with conventional tubes and no associated short-term complications were noted. However, having been introduced in a non-healed temporary tracheostomy, granulation tissue formation was noted when dogs wore the TS for longer than 5 days.

The aim of this case report is to document the care and outcome in two brachycephalic dogs with a completely healed PT, which wore a silicone TS long term. The dogs had been experiencing intermittent episodes of airway obstruction, and the TS was inserted to ensure airway patency and facilitate stoma care. We also want to introduce the possibility of 3D printing a custom-designed device.

## 2 | MATERIAL AND METHODS

### 2.1 | Cases

#### 2.1.1 | Case 1

An 8-year-old, 7.5 kg, male castrated pug was presented for a history of inspiratory dyspnea, which it had experienced from the age of 6 months. A staphylectomy, a right-sided turbinectomy and a rhinoplasty had been performed in another institution 6 years prior. For 2 years, clinical symptoms of inspiratory dyspnea and regurgitation had improved, only to gradually worsen over the years. At presentation, the owners reported that the dog constantly struggled to breathe, had episodes of syncope, and regurgitated daily.

Clinical examination revealed a brachycephalic phenotype, a laryngeal stridor, and an elevated breathing rate of 52/min. The hematology showed a monocytosis with (1204.28/ $\mu$ l, Reference <500/ $\mu$ l), the chemistry profiles were within normal ranges. Thoracic radiographs were unremarkable. A computed tomography examination revealed findings attributable to the previous surgery (right-sided absence of nasal turbinates, relatively thin and short soft palate), and there was evidence of marked laryngeal swelling. Subsequent laryngoscopy found a stage-III LC and severe laryngeal edema. As corrective possibilities of the upper airways had been exhausted, a left-sided

laryngeal tie back (combined cricoarytenoid and thyroarytenoid lateralization) as described by White,<sup>3</sup> was performed. After extubation, the dog displayed marked inspiratory dyspnea with laryngeal stridor. Thus, a temporary tracheostomy was conducted. After the procedure the dog recovered uneventfully and was hospitalized in the intensive care unit for tube care. On day 4, tracheal obstructions of the tracheostomy tube continued to result in dyspnea. After obtaining the owner's consent, the dog was prepared for PT (refer to Procedure 1 in the surgical procedures section below).

After suture removal, 14 days post PT, the owners were instructed with stoma care and the dog was discharged. On follow up 1 month after surgery, the dog's breathing had improved markedly and the expectation of sputum had further waned. However, the tracheostomy had constricted and the dog occasionally developed dyspnea when in a position that caused the stoma to collapse. On clinical examination it was found that the stoma was reduced in size by approximately 20% and there was residual loose skin immediately surrounding the stoma, resulting in position-dependent obstruction of the tracheostomy. The owners were made aware of the possibility to insert a silicone TS to distend the tracheostomy as published by Trinterud et al.,<sup>10</sup> and were informed that only a limited number of dogs had been treated with this device to date and none were known to permanently wear the TS after a PT had been performed. Possible complications such as pressure necrosis, dislocation of the TS, allergic reactions to the silicone, bleeding from the stoma, and development of granulation tissue were discussed. The owners signed the informed consent, and the dog was scheduled for removal of excessive skin of the ventral neck and first fitting of a silicone TS (refer to Procedure 2 in the surgical procedures section below).

### 2.1.2 | Case 2

A 9-year-old, 15 kg, male castrated French bulldog was referred for an acute episode of severe inspiratory dyspnea. The dog had experienced breathing difficulties attributable to BOAS since weaning, and had undergone a staphylectomy, removal of the laryngeal sacculles, and rhinoplasty in another institution 6 years prior. The owner reported a satisfactory amelioration of inspiratory dyspnea until 4 months ago, when the dog again exhibited progressing signs of dyspnea. The dog suffered syncope-like episodes and struggled to breathe while sleeping.

The dog presented with inspiratory dyspnea and had cyanotic mucus membranes when handled. The diagnosis of stage III LC was made during laryngoscopy and after exclusion of other pathologies in the oral cavity. A

PT was performed with owner consent (refer to Procedure 1 in the surgical procedures section below). After suture removal, the dog was released from the ICU into home care.

The owner had no difficulties caring for the PT at home but reported that the stoma was sometimes obstructed when the dog was lying in lateral recumbency. Then the opening was longitudinally compressed and covered by loose skin that surrounded the stoma. The owner was informed about the possibility of using a TS, and after she was counseled about possible complications, she consented. The first stent insertion took place during a follow up 1 month after the PT procedure (refer to Procedure 2 in the surgical procedures section below). The tracheal stoma had healed well and was minimally constricted.

## 2.2 | Surgical procedures

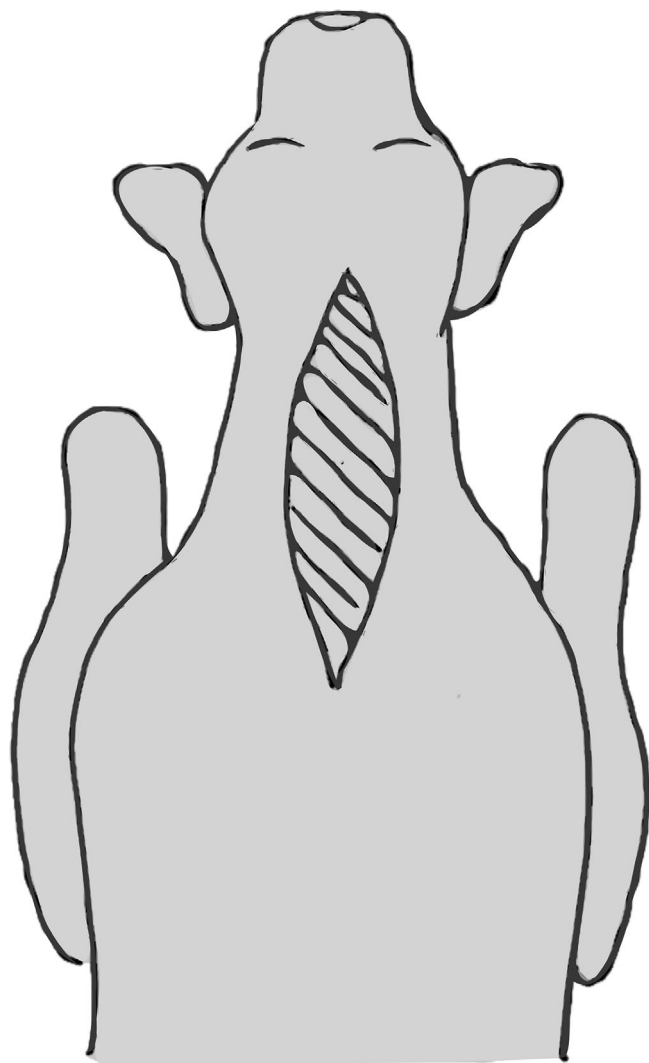
### 2.2.1 | Procedure 1: Combined permanent tracheostomy and removal of excess skin from the dorsal neck

To remove excess loose skin that may occlude the stoma, an elliptical area of skin was removed from the median dorsal neck, as depicted in Figure 1. Afterwards, the dog was placed in dorsal recumbency and the ventral neck area was aseptically prepared and a PT was created following the method published by Hedlund et al.<sup>11</sup> In Case 1, the existing temporary tracheostomy was utilized as the cranial termination of the stoma and the novel PT spanned from the 4th to 8th tracheal ring.

The dogs were kept in the ICU for surveillance and PT care until suture removal, which took place 14 days after surgery. During the first days, both dogs experienced potentially life-threatening episodes of dyspnea, due to clogging of the stoma with mucus. This issue subsided with time and the production of mucus had almost normalized at the time of the dogs being released into home care.

### 2.2.2 | Procedure 2: Excision of excess skin around the tracheal stoma and insertion of the silicone tube

Both dogs had surplus mobile skin around their PT. Thus, a "U"-shaped skin excision around the stoma was performed during the same anesthesia, as the silicone stent was first inserted (Figure 2). In Case 1, the curve of the "U" was directed cranially; in Case 2, the curve was directed caudally (see also Figure 3).

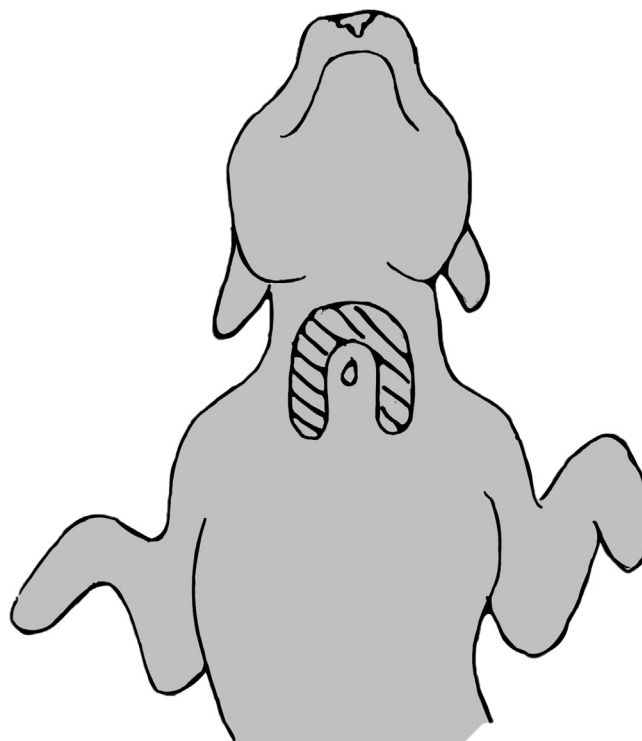


**FIGURE 1** Schematic illustration of the location and amount of loose skin for excision. The amount of skin that needed to be removed was determined in the dog by skin mobilization while it was awake.

After confirming adequate healing of the tracheostomy and presence of a mucocutaneous connection, both dogs were fitted with a double flared standard silicone TS (Crazy Factory GmbH, Chur, Switzerland), sized 8 mm (Case 1) and 10 mm (Case 2) in outer diameter. The largest possible device was chosen that could be inserted into the stoma easily without stretching it. As described by Trinterud et al.,<sup>10</sup> the TS was compressed to an ellipsoid shape and then was then slid carefully into the stoma.

### 2.3 | Stent care

Long-term care consisted of cleaning of the visible parts of the stent and its surroundings with a moist cotton



**FIGURE 2** Schematic illustration of the location and amount of loose skin for excision during Procedure 2. The amount of skin that needed to be removed was determined in the standing dog by skin mobilization.

swab twice daily, and weekly removal of the TS and cleaning of the silicone with warm water and mild soap. The dog used a commercial inhalator with vaporized tap water twice daily. The owners were able to remove and reinsert the TS themselves. Medication was continued for 3 months and consisted of metoclopramide 0.2 mg/kg orally twice daily and acetylcysteine (5 mg/kg twice daily with meals).

## 3 | RESULTS

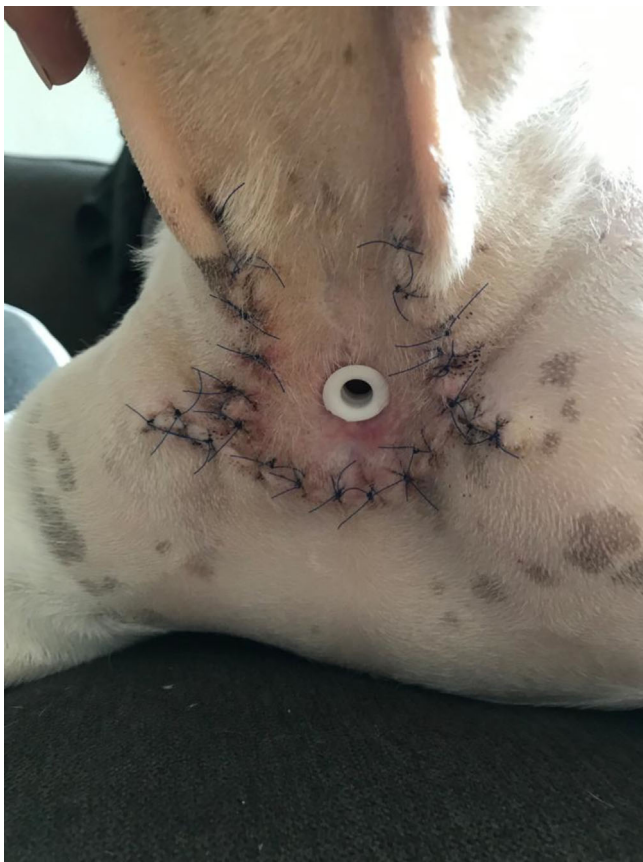### 3.1 | Case 1

The owners reported a marked improvement in quality of life with the dog free of dyspnea and able to exercise. The TS was tolerated well and the dog showed no signs of discomfort. The owners were comfortable with stent care and removed the device once a week for cleaning. They reported that the required cleaning frequency of the stoma periphery was declining over time as mucus production decreased. Starting with cleaning the skin around the TS with moistened cotton swabs 4–5 times daily, it was done later once or twice daily. When removing the TS, they left it out for some hours but reported that a

mild positional dyspnea was present, and the dog seemed to be less comfortable. Thus, the TS was deemed necessary. The owners felt that the TS facilitated stoma care and that they felt more confident when it was in place, as the TS supported the opening. When they took their dog for a walk, they would protect the tracheal stoma with a custom-made scarf with a window of large-meshed fabric. The dog did not inadvertently lose the silicone stent, even when exercising.

On follow ups, the stoma did not change its general appearance and there were no bleeding or tissue necrosis observed when externally examined. (Figure 4).

A follow-up tracheoscopy was conducted 1 year after first insertion of the TS to check for secondary changes to the tracheal mucosa, such as granulation tissue formation or pressure necrosis. The TS was removed for the procedure. Endoscopic examination of the tracheal stoma under general anesthesia revealed that the tracheostomy had healed satisfactorily, with minor signs of granulation tissue in areas in direct contact with the flares of the TS (Figure 5).



**FIGURE 3** Appearance of Case 2 2 weeks after removal of surplus skin and insertion of the stent. Note the device's flanges, which have been cut by the owner to alleviate skin sores.

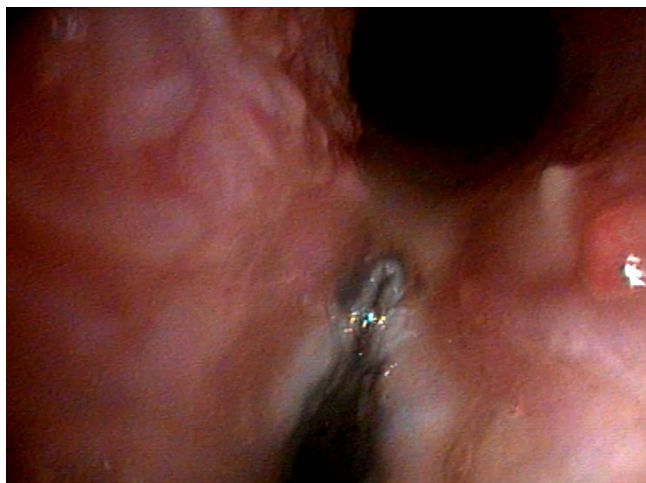Two years after first insertion of the TS, the owners were contacted and the dog was reported to be alive and well.

### 3.2 | Case 2

The dog in Case 2 was released the same day after full recovery from Procedure 2. TS care was well tolerated, and the owner was comfortable with stent removal and reinsertion and did not need assistance by another person. The dog's quality of life had markedly improved, as it was alert and active. The owner on occasion tried removing the stent for longer periods of time but observed the dog intermittently showing signs of dyspnea



**FIGURE 4** Final appearance of Case 1 with the tracheal stent in place.



**FIGURE 5** Still image of the follow-up tracheoscopy performed 1 year after first stent insertion (Case 1). Note the mild granulation tissue formation in the area of contact with the flanges.

and inspiratory stridor depending on body position. Thus, the owner felt more at ease leaving the TS *in situ*. It also appeared that the device prevented clogging of the stoma, as mucus did not adhere to the silicone and any debris was easily wiped with a moistened cotton swab.

After approximately 2 weeks of wearing the device, it was noticed that the skin immediately in contact with the edges of the TS developed sores. It was suspected this was due to pressure and rubbing from the flanges. Modification of the edges by cutting led to a slight improvement but no resolution (Figure 3). We hypothesized that this problem would resolve if a TS of a minimally increased length were used, as the stent was 1–2 mm shorter than the depth of the stoma from skin surface to tracheal opening. Stents from different producers were investigated but all had a maximum length of 10 mm.

We contacted a manufacturer specialized in 3D printed silicone products (Spectroplast, Zurich, Switzerland), who printed customized medical-grade silicone TS with lengths of 11 and 12 mm and rounded flanges to reduce irritation (Figure 6). The skin lesions healed with the 11 mm device in place. However, the material (Truesil A50) was slightly stiffer and thus more difficult to fold for insertion. After approximately 6 weeks of usage (six times removal, cleaning, and reinsertion), the 3D-printed TS developed a crack when the owner removed it. The owner therefore did not use the 3D printed stents for longer than 3–4 weeks before discarding them. Like with the commercial TS, the dog showed no signs of discomfort when wearing the 3D-printed specimen. However, unlike Case 1, in which the dog played enthusiastically, the stent occasionally fell out. During a follow-up examination, it was found that the stoma



**FIGURE 6** Comparative image of the 3D-printed silicone stent on the left and the commercially available stent on the right. Note the 1 mm increased length and rounded flanges of the 3D printed device.

had widened minimally and a TS of 12 mm outer diameter was a better fit. With this device in place, the dog would not lose the stent any more during exercise.

Nine months after PT, the owner noticed bloody ejections from the tracheal stoma and the dog intermittently had swallowing problems. Laryngoscopy *alio loco* revealed a 1 cm, pediculated, irregular mass that originated from the right cricoid and the histopathologic examination revealed a fibrosarcoma. The owner did not opt for further oncologic treatment. The dog's condition improved after removal of the mass and remained good for another 3 months. Then it gradually lost weight over a month's duration and was euthanized for suspicion of mass recurrence and paraneoplastic disease when bloody ejections from the stoma recommenced.

## 4 | DISCUSSION

With this case report we aim to introduce the use of a silicone TS to improve long-term care of dogs with PT. Both of the dogs in this report underwent PT as a salvage procedure for stage III LC. This condition was a secondary result of BOAS, for which previous surgical therapies had failed. Both dogs were reported to experience breathing difficulties in certain situations, such as lateral recumbency, possibly because of redundant skin folds covering the stoma or longitudinal collapse of the stoma. Relating to the study by Trinterud et al.,<sup>10</sup> we decided to use the silicone TS to prevent occlusion of the stoma. Insertion and removal of the TS were easily feasible in a dog that was awake and the owners were confident removing, cleaning, and reinserting the TS at home. Moreover, they

reported feeling more confident in their dogs' safety when the TS was in place, because they no longer observed dyspnea related to stoma occlusion.

Case 1 was a small and slim pug, that tolerated the standard commercial stent very well with minimal signs of secondary changes on tracheoscopy after 1 year of wear. Case 2 was a French bulldog and this dog developed skin lesions surrounding the edges of the outer TS flanges. We hypothesized that they were caused by the device's length being slightly too short and causing pressure on the edges. A specialized manufacturer of medical-grade silicone custom-designed 3D-printed silicone stents with an increased length and rounded flanges, and, after insertion, the skin lesions surrounding the stent healed. Consequently, it is advised to custom-design a 3D-printed TS, if a commercial TS is deemed too short during first insertion, or if pressure sores are encountered after the first days of wear.

The 3D printed material was more friable than the commercial silicone and the stent developed a crack after several rounds of removal and reinsertion, which prompted the owner to replace the TS more frequently. The medical grade 3D-printable silicone used in this study is available with different material properties. Thus, a larger prospective study is needed to determine the best silicone material for this use.

Trinterud et al., who inserted the TS in nonhealed temporary tracheostomies for short-term care, reported a 60% rate of excessive granulation tissue formation in dogs that wore the TS for 5 days or longer.<sup>10</sup> The dogs in our study did not encounter this problem, as the mucocutaneous junction of their PT had fully healed before the stents were inserted. Care was also taken to choose a stent diameter that fit well into the tracheostomy without exerting excessive pressure on the mucocutaneous junction.

A possible complication resulting from excessive granulation tissue formation encountered by Trinterud et al. is TS dislodgement.<sup>10</sup> The dog in Case 2 of our study experienced intermittent loss of the TS 6 months after first insertion due to widening of the tracheal stoma. This issue was resolved because a TS with a 2 mm increased outer diameter could now be inserted. Dislodgement of the TS into the trachea has been contemplated as possible complication but was deemed unlikely, as the length and outer dimensions of the TS were markedly larger than the inner diameter of the trachea and the silicone used for the stents made them sufficiently rigid not to be deformed easily.

As a conclusion, the insertion of a silicone TS into a completely healed permanent tracheal stoma was beneficial in the two cases we observed. Before stent

insertion, the dogs experienced complications of stoma occlusion, and introduction of the devices was perceived to facilitate stoma care for the owners and increased the owners' confidence in airway patency. As the TS led to widening of the stoma in one dog, a further possible indication is prevention or improvement of excessive stoma constriction in dogs that do not qualify for revision surgery. In dogs with special anatomic requirements, the use of a customized 3D-printed device can be considered.

## ACKNOWLEDGMENTS

**Author Contributions:** Janssen JN, DVM: Clinically responsible for the cases, collected case data, drafted the manuscript, managed correspondence. Liehmann L, DVM, DECVS: Provided advice during case management, assisted the first author in writing the manuscript. Gradner G, DVM, Diplomate ECVS: Provided advice during case management, assisted first author in writing the manuscript.

## CONFLICT OF INTEREST STATEMENT

The authors have no conflicts of interest to declare. The 3D printed samples were provided by Spectroplast without charge or obligation.

## ORCID

Janina N. Janssen  <https://orcid.org/0000-0001-5056-518X>

## REFERENCES

- Leonard HC. Collapse of the larynx and adjacent structures in the dog. *Javma*. 1960;137:360-363.
- Harvey CE, Venker-von Haagan A. Surgical management of pharyngeal and laryngeal airway obstruction in the dog. *Vet Clin North Am*. 1975;5:515-535.
- White RN. Surgical management of laryngeal collapse associated with brachycephalic airway obstruction syndrome in dogs. *J Small Anim Pract*. 2012;53:44-50.
- Harvey CE. Review of results of airway obstruction surgery in the dog. *J Small Anim Pract*. 1983;24:555-559.
- Chan A, Liu L, Ladlow J. Efficacy and complication rate of cuneiformectomy in dogs with brachycephalic obstructive airway syndrome (BOAS). *Short Communications ST + Oncology*. 32nd ed. Annual Scientific Meeting. 2023;150.
- Collivignarelli F, Bianchi A, Vignoli M, et al. Subtotal Epiglottectomy and ablation of unilateral arytenoid cartilage as surgical treatments for grade III laryngeal collapse in dogs. *Animal*. 2022;9:12.
- Occhipinti LL, Hauptman JG. Long-term outcome of permanent tracheostomies in dogs: 21 cases (2000–2012). *Can Vet J*. 2014;55:357-360.
- Davis AM, Grimes JA, Wallace ML, et al. Owner perception of outcome following permanent tracheostomy in dogs. *J Am Anim Hosp Assoc*. 2018;54:285-290.

9. Gobbetti M, Romussi S, Buracco P, Bronzo V, Gatti S, Cantatore M. Long-term outcome of permanent tracheostomy in 15 dogs with severe laryngeal collapse secondary to brachycephalic airway obstructive syndrome. *Vet Surg*. 2018;47:648-653.
10. Trinterud T, Nelissen P, White RAS. Use of silicone tracheal stoma stents for temporary tracheostomy in dogs with upper airway obstruction. *J Small Anim Pract*. 2014;55:551-559.
11. Hedlund CS, Tangner CH, Montgomery DL, et al. A procedure for permanent tracheostomy and its effects on tracheal mucosa. *Vet Surg*. 1982;11:13-17.

**How to cite this article:** Janssen JN, Gradner GM, Liehmann L. Long-term outcome of permanent tracheostomy management in two brachycephalic dogs using a commercial and a three-dimensional-printed silicone stent. *Veterinary Surgery*. 2024;53(4):761-768. doi:[10.1111/vsu.14085](https://doi.org/10.1111/vsu.14085)