

# Minimal complications observed with a modified surgical approach for treatment of canine anal sac neoplasia

Carolyn L. Chen, DVM; Janis M. Lapsley, DVM; Laura E. Selmic, BVetMed, MPH\*

Department of Veterinary Clinical Sciences, College of Veterinary Medicine, The Ohio State University, Columbus, OH

\*Corresponding author: Dr. Selmic (selmic.l@osu.edu)

## OBJECTIVE

To describe a modified approach to closed anal saccullectomy and report the short-term outcomes of dogs that underwent the procedure for treatment of neoplasia.

## ANIMALS

16 client-owned dogs.

## PROCEDURES

Medical records of 1 referral hospital were reviewed to identify dogs that underwent modified closed anal saccullectomy for treatment of anal sac neoplasia between January 2018 and September 2020. Data collected included signalment, examination and diagnostic imaging findings, surgical details, intraoperative and postoperative complications, cytologic and histologic findings, adjuvant treatments, duration of follow-up, and short-term outcome.

## RESULTS

15 dogs had apocrine gland anal sac adenocarcinoma, and 1 had a collision tumor. No dogs had intraoperative complications; 1 dog had a minor postoperative complication (paraparesis) that resolved. The median duration of postoperative follow-up was 286 days (range, 67 to 777 days). One dog had confirmed local disease recurrence 290 days after surgery, and 1 had suspected local disease recurrence 203 days after surgery and was euthanized because of systemic disease progression.

## CONCLUSIONS AND CLINICAL RELEVANCE

The modified closed anal saccullectomy was well tolerated in this sample of dogs, with minimal short-term complications. This study provided evidence to justify evaluation of the procedure in a larger number of dogs and assessment of the effects of procedural modifications on postoperative complication rates and time to local recurrence.

There are several indications for surgical removal of the anal sacs in dogs, including neoplasia, recurrent impaction, development of anal sac sinuses, chronic anal sacculitis, unresolved abscesses, and failure of medical treatment for other anal sac conditions.<sup>1</sup> Closed and open techniques for anal saccullectomy have been described, with a low incidence of major complications associated with either procedure.<sup>2-6</sup> The open technique allows complete removal of the anal sac duct and orifice but carries a higher risk of postoperative contamination, tumor dissemination, and possible trauma to the external anal sphincter.<sup>7</sup> Closed anal saccullectomy decreases some of these risks, as the anal sac is removed without penetration of the lumen. Several techniques have been described to delineate the anal sac when neoplasia is not suspected.<sup>6,8-12</sup> The anal sac duct is not fully excised when the closed technique is used. Traditionally, the skin approach described for closed anal saccullectomy is a semilunar, perianal incision that allows for exposure of the anal sac but does not optimize dissection and isolation of the duct. This is

a disadvantage, especially when surgical removal of an anal sac neoplasm is performed. Leaving a portion of the duct behind could feasibly contribute to local tumor recurrence, and difficulty with dissection can increase surgery time, tissue handling, and patient discomfort after surgery.

In an effort to mitigate these problems, the authors have been performing a modified approach to closed anal saccullectomy involving complete removal of the anal sac duct. During surgery, the anal sac duct can be used for manipulation of the anal sac and associated tumor. The objective of the study reported here was to describe the modified technique and report complications and short-term outcome in dogs undergoing this procedure for treatment of anal sac neoplasia.

## Materials and Methods

### Case selection

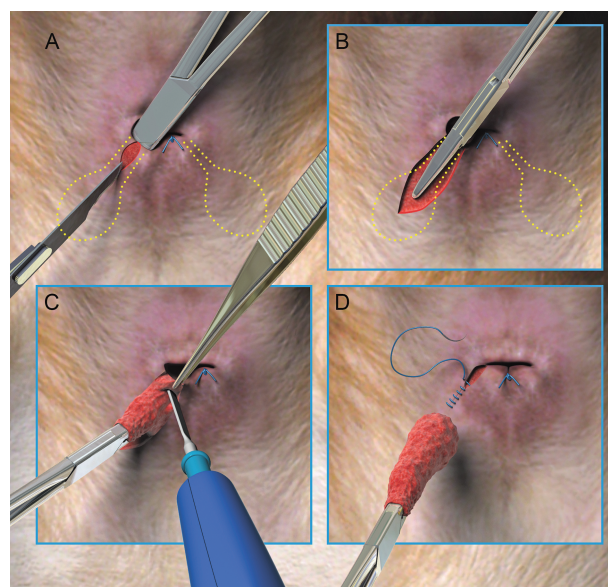
Electronic medical records of The Ohio State University College of Veterinary Medicine were searched

to identify dogs that underwent the modified technique for closed anal saccullectomy between January 1, 2018, and September 30, 2020. Search terms included anal saccullectomy and anal sac mass. To be included in the study, dogs were required to have complete medical records including surgery reports and histologic examination results, with  $\geq 30$  days of clinical follow-up data available. Follow-up was performed by 1 investigator (CLC) with the referring veterinarian if there was no documented examination  $\geq 30$  days after surgery on record at our institution; owner follow-up via email was attempted if the data were not available from the referring veterinary clinic.

### Medical records review

Data collected from the medical records included signalment and examination findings at the time of surgery, results of any preoperative laboratory analyses, and results of diagnostic imaging or other diagnostic tests (eg, fine-needle aspiration) if applicable. The anesthesia and surgery records were reviewed, and details of the surgical procedure, including concurrent procedures that were performed and any complications that developed during surgery were recorded. Surgery time was recorded from the time of the initial incision to completion of skin closure. Perioperative and postoperative antimicrobial administration and adjuvant treatments (chemotherapy or radiation therapy) were noted. Postoperative complications, histologic examination findings for excised tissues, development of local disease recurrence and any treatments pursued, date of last follow-up, and date and cause of death or reason for euthanasia were annotated if applicable.

A complication was defined as any adverse event associated with surgical intervention, with intraoperative complications occurring between the time of skin incision and closure, and postoperative complications developing after skin closure.<sup>13</sup> Intraoperative complications were graded (from 0 [no deviations from the ideal surgical course] to IV [intraoperative death]) by use of the Classification of Intraoperative Complication system.<sup>13,14</sup> Postoperative complications were graded according to the Contracted Accordion Severity Classification system (from 1 [mild complications] to 4 [postoperative death]).<sup>13,15</sup> Postoperative complications were classified as short-term if they were evident during the postoperative period up to the time of hospital discharge and resolved by the time of recheck examination 10 to 14 days after surgery, and after treatment, if necessary, was initiated. Postoperative complications were classified as long-term if they started or persisted after the time of suture removal and recheck examination. A sequela was defined as a residual disease or condition that developed after surgery and was inherent to the procedure.



**Figure 1**—Digital illustrations depicting the modified closed anal saccullectomy technique used in dogs of the present study. A—Mosquito hemostats were inserted into the anal sac duct opening to confirm anal sac location, and a radial skin incision was made over the length of the duct and sac. B—After dissection of subcutaneous tissue and isolation of the duct, the hemostat was removed and opened. One side of the jaws was placed into the duct and clamped to assist with manipulation and traction. C—Electrocautery was used to dissect the duct, anal gland, and associated tumor away from surrounding anal sphincter fibers and subcutaneous tissues. D—The external anal sphincter tissue was apposed with absorbable monofilament suture in a simple interrupted pattern, and the remainder of closure was routine. Images created by Tim Vojt and reproduced with the permission of The Ohio State University. ©The Ohio State University.

### Surgical procedure

An example of the modified closed anal saccullectomy procedure is provided (**Supplementary Video S1**). The protocols for induction and maintenance of anesthesia and analgesia were at the discretion of the clinician and anesthesiologist who managed the case. Surgeries were performed with the dog in ventral or dorsal recumbency and under general anesthesia. A purse-string suture was placed at the mucocutaneous junction, allowing access to the anal sac ducts. A mosquito hemostat was placed into the affected anal sac duct, and a skin incision was made along the length of the duct with a scalpel blade (**Figure 1**). Monopolar electrocautery was used to incise subcutaneous tissue and anal sphincter muscle fibers to isolate the duct. The hemostat was removed and opened; one side of the jaws was placed into the duct, and the duct was clamped in the hemostat to assist with manipulation and traction. Electrocautery was used to dissect the duct, anal gland, and associated tumor from surrounding anal sphincter fibers and subcutaneous tissues. The external anal sphincter tissue was apposed with absorbable monofilament suture in a simple interrupted pattern, and

the remainder of the closure was routine. The purse-string suture was removed after closure, and dogs were monitored routinely throughout recovery.

## Statistical analysis

Continuous variables were assessed for normality with Shapiro-Wilk tests and were reported as median and range if nonnormally distributed or mean  $\pm$  SD if normally distributed. The duration of local disease control was calculated as the number of days from the date of surgery to the date of detected local recurrence. The median duration of follow-up was calculated as the number of days from the date of surgery to the date of death, euthanasia, or last follow-up. Commercially available statistical software (Prism, version 8, GraphPad Software Inc; Microsoft Excel, Microsoft Corp) was used to calculate descriptive statistics.

## Results

### Dogs

Sixteen dogs were identified that met inclusion criteria. The median age at the time of surgery was 11.5 years (range, 5 to 14.8 years). Four dogs were females, and 12 were males. All dogs were neutered. There were 8 mixed-breed dogs, 2 Golden Retrievers, and 1 each of 6 other breeds. The mean  $\pm$  SD body weight at the time of surgery was  $21.2 \pm 10.6$  kg, with an overall range of 4.8 to 32.7 kg.

### Clinical findings

Fifteen dogs had unilateral, palpable anal sac masses and 1 dog had bilateral disease. The median greatest dimension of the anal sac mass found on physical examination ( $n = 15$  dogs) was 17.5 mm (range, 2.0 to 60.0 mm); the mass dimensions were not recorded following physical examination for 1 dog. All dogs had a preoperative CBC and serum or plasma biochemical analysis performed, and 2 dogs had hypercalcemia. No other relevant abnormalities were detected in the remaining 13 dogs. Fourteen dogs had fine-needle aspiration and cytologic examination of the lesion performed, and all had findings consistent with carcinoma. All dogs underwent diagnostic imaging for staging purposes before surgery. These procedures included thoracic radiography ( $n = 15$ ), abdominal ultrasonography (8), and CT (10). Multiple dogs underwent  $> 1$  type of imaging procedure. Seven dogs were suspected to have metastatic disease affecting lymph nodes in the iliosacral lymph basin on the basis of diagnostic image evaluation; 3 of these 7 dogs had fine-needle aspiration and cytologic examination of lymph node samples that confirmed metastatic disease.

Five dogs had aspirates of  $\geq 1$  organ (liver [ $n = 4$ ] and spleen [3]) performed, and none had evidence of metastatic disease in those organs. One dog had a concurrent diagnosis of transitional cell carcinoma of the urinary bladder that was identified during the

preoperative work-up, and 1 other dog had a mass in the caudal aspect of the abdomen that was removed under the same anesthetic episode as the anal saccullectomy and was histologically diagnosed as a well-differentiated hemangiosarcoma.

### Surgery

All surgeries were performed by 1 of 2 authors (LES or JML;  $n = 9$ ) or 1 of 5 surgical residents (7) under direct supervision of 1 of the same 2 authors. Eleven dogs were positioned in sternal recumbency for the procedure, and 5 were positioned in dorsal recumbency for abdominal procedures prior to anal saccullectomy in the same position. Abdominal procedures performed included iliosacral lymph node extirpation ( $n = 3$ ), removal of a caudal abdominal mass (1), and right medial liver lobectomy with omental mass removal (1).

The anesthesia record for 1 dog could not be retrieved. The mean  $\pm$  SD surgical time was  $47.5 \pm 11.6$  minutes for the remaining 10 dogs that had anal saccullectomy performed without concurrent procedures. The mean  $\pm$  SD surgical time for anal saccullectomy performed by the authors, with no concurrent procedures, was  $51 \pm 8.9$  minutes ( $n = 5$ ), and that for anal saccullectomy performed by a surgical resident, with no concurrent procedures, was  $44 \pm 13.9$  minutes (5).

All dogs received ampicillin-sulbactam (30 mg/kg, IV) once at induction and every 90 minutes during surgery. Fifteen of the 16 dogs were prescribed amoxicillin-clavulanic acid (13.75 mg/kg, PO, q 12 h) at the time of hospital discharge as part of surgical prophylaxis; the length of antimicrobial treatment ranged from 5 to 14 days.

### Histologic diagnoses

The histologic diagnosis for the anal sac mass was consistent with the described preoperative cytologic findings for the 14 dogs that had this procedure performed. Fifteen dogs had a histologic diagnosis of apocrine gland anal sac adenocarcinoma (AGASCA), and 1 dog had a diagnosis of a collision tumor composed of AGASCA and soft tissue sarcoma. The 3 dogs that had iliosacral lymph node extirpation at the time of anal saccullectomy all had evidence of metastatic disease in these tissues on histologic examination.

### Short-term complications

None of the dogs had intraoperative complications (all were assigned a grade of 0) during the procedure. One dog developed a grade 1 postoperative complication of paraparesis, which was suspected to be secondary to epidural analgesic administration, acute noncompressive nucleus pulposus extrusion, or fibrocartilaginous embolism. Advanced imaging was recommended but declined by the owner. This dog was monitored in the hospital for 2 days and had a physical therapy session on the second day before being discharged. At the 2-week follow-up



examination, the paraparesis was documented as markedly improved, and the paraparesis was documented as resolved at the next follow-up examination 4 months after surgery. All dogs were doing well with no reported concerns at the time of incision recheck examination 10 to 14 days after surgery.

### Local recurrence and short-term clinical outcome

At the time of case accrual, 8 dogs had been euthanized, and 7 dogs were alive. One dog was lost to follow-up with the referral veterinarian 459 days after surgery, and owner contact attempts were unsuccessful. Two of the 8 dogs were euthanized because of disease progression: one had local recurrence, and the other had systemic disease. The other 6 dogs were euthanized because of disease processes unrelated to AGASCA. Two of the 16 dogs in the study had confirmed or suspected local recurrence; the duration of local disease control was 290 and 203 days, respectively. The median duration of follow-up was 286 days postoperatively (range, 67 to 777).

No dogs received neoadjuvant treatment or radiation therapy. Four dogs underwent adjuvant chemotherapy (carboplatin, 300 mg/m<sup>2</sup>/dose, IV) in addition to surgery; 1 dog received 3 doses, 2 dogs received 4 doses, and 1 dog received 6 doses. Two dogs (1 that received 3 doses of carboplatin and 1 that received 4 doses) were doing well at the time of last follow-up and had no evidence of disease recurrence. One dog that received 4 doses of carboplatin was euthanized 118 days after surgery for reasons unrelated to AGASCA.

The dog that received 6 doses of carboplatin had an anal sac mass with a diameter of 3 cm at the time of surgery, and histologic examination of the first tumor revealed a high-grade AGASCA with a mitotic index of 25/10 hpf. An anal sac mass at the previous surgical site was detected 290 days postoperatively on rectal examination by the primary veterinarian, and cytologic examination of a fine-needle aspirate confirmed local recurrence of AGASCA. The owner elected medical management; on examination 433 days after surgery, the continued presence of a mass was confirmed. At last follow-up (459 days after surgery), medical management, including orally administered prednisone and gabapentin, was ongoing.

Another dog had suspected local recurrence but the mass did not undergo cytologic examination or biopsy. The mass for which the dog had undergone surgery was 4 cm in diameter, and histologic analysis revealed a high-grade AGASCA with a mitotic index of 27/10 hpf. This dog underwent abdominal ultrasonography 68 days after surgery, and the results revealed left internal iliac lymphadenopathy. Fine-needle aspiration was performed, and cytologic findings were consistent with granulomatous inflammation but neoplasia could not be ruled out. Thoracic radiographs obtained at that time did not show metastatic disease. Repeated abdominal ultrasonography 131 days after

surgery revealed progressive lymphadenopathy with the addition of right sublumbar lymphadenopathy. The lymph nodes could not be safely sampled with ultrasound guidance, and thoracic radiographs did not show evidence of metastatic disease. On physical examination 203 days after surgery, there was frank blood present with rectal wall deformation strongly suggestive of local disease recurrence. Because of the severity of clinical signs (dyschezia and anorexia), the dog was euthanized. No additional diagnostic tests were performed.

One dog was ultimately euthanized because of systemic signs suspected to be related to hypercalcemia. The record indicated the dog was doing well 105 days after surgery, with serum total calcium concentration within the reference range. However, progressive hypercalcemia was documented 398 and 455 days after surgery. Thoracic radiographs were concurrently obtained 455 days after surgery and revealed no radiologic evidence of pulmonary metastatic disease. The dog was euthanized 468 days after surgery because of lethargy and anorexia.

### Discussion

The modified closed anal saccullectomy procedure was well-tolerated by the dogs in the present study. None of the dogs had intraoperative complications, and only 1 of 16 dogs had a postoperative complication, which was minor (grade 1) and not considered directly related to the surgical procedure.

There are several potential advantages of the technique described in the present report. The use of the clamped hemostats on the duct allows for controlled manipulation of the tissue during dissection. Notably, this allows traction to be placed on the tissue to be excised, with minimal manipulation of the immediate adjacent soft tissue. The use of mosquito hemostats allows for this technique to be performed in patients of various sizes. It is possible that clinicians may experience challenges related to use of the hemostats in smaller dogs and cats. However, the use of smaller hemostats could aid in placement in these patients.

Clinicians who perform traditional closed anal saccullectomy procedures can often transect the anal sac duct at its junction with the anal planum; however, this is not consistently done, and it can potentially leave diseased duct tissue behind. The modified technique used in dogs of the present study facilitates consistent removal of the anal sac and duct in its entirety, which may increase surgical margins in this location and impact local recurrence rates. Authors of a retrospective study<sup>16</sup> who evaluated the records of 42 dogs that underwent surgical and adjuvant treatment of AGASCA reported that 2 (5%) dogs had local tumor recurrence. Another retrospective study that included 34 dogs with early-stage AGASCA treated by means of surgery alone found that 7 (20%) dogs had local recurrence.<sup>17</sup> Two of 16 (13%) dogs in the study



reported here had suspected or (cytologically) confirmed local tumor recurrence, which was identified 203 days after surgery for one dog and 290 days after surgery for the other. The dog that had confirmed local recurrence had adjuvant medical treatment, whereas the dog with suspected recurrence did not. It was not possible to directly compare the results of the present study with findings for dogs that underwent anal saccullectomy in previous studies, given the variations in disease burden, clinical management, and follow-up times. Further studies that include larger numbers of dogs, selection of cohorts with comparable disease burdens, and appropriate long-term follow-up would be needed to determine whether there are differences in short- or long-term outcomes and local recurrence rates following anal saccullectomy with the modified closed anal saccullectomy technique, compared with traditional approaches.

A clinically important advantage of the technique described here is its relative simplicity and ease of learning. Seven of the surgeries in the present study were performed by residents, who all subjectively felt that this approach was straightforward and easily adopted. In the authors' experience, a somewhat common problem encountered for less experienced surgeons is finding the anal sac when the neoplastic lesion is small. The traditional skin approach for closed anal saccullectomy involves a semilunar incision over the anal sac; however, on occasion the incision is lengthened to allow better visualization if more intensive dissection is required. For the modified technique, the skin approach that follows the duct allows for direct visual access to the entire duct so that it can be used for traction and immediate localization of the anal sac. This eliminates guesswork, resulting in ease of removing small anal sac masses that are not easily palpable from the skin surface. The authors believe that this technique can be easily taught and widely applied to clinical practice.

Although there were no major postoperative complications reported in the present study, there are some possible disadvantages to the modified closed anal saccullectomy technique. The radial skin incision is similar to the approach used in the traditional open anal saccullectomy technique and is much closer to the anus than the semilunar incision used for the traditional closed anal saccullectomy technique, which may predispose patients to infection. All skin closures in the present study were performed with intradermal suture placement and appropriate skin apposition. All dogs except one received postoperative antimicrobial treatment, and none of the dogs experienced surgical site infection. Another consideration for the modified technique, compared with other methods, is the increased amount of anal sphincter muscle dissection needed to remove the duct, which requires careful reapposition of the tissues. However, none of the dogs in this study developed fecal incontinence.

All of the dogs in the study reported here had surgery because of neoplastic disease. Although, to the authors' knowledge, this modified technique has only been performed on dogs with anal sac neoplasia, we are confident that it can be extrapolated for use in dogs with other anal sac disease conditions for which surgery is indicated, such as chronic anal sacculitis, recurrent impaction, and anal sac abscesses. Because this technique allows for removal of the anal sac and entire duct, it could theoretically be performed in lieu of open anal saccullectomy in certain cases.

The focus of the present study was the description of a modification of a surgical technique and the short-term outcomes of dogs that underwent the procedure. Several limitations precluded further conclusions from being drawn, including the retrospective design, small number of cases, and variations in disease burden and management. The disease stage of the dogs prior to surgery varied widely, and adjuvant treatment was pursued in some but not all cases. These factors certainly could have affected the results in the study sample. The lack of longer-term follow-up also could have influenced the detected rate of local disease recurrence. Many clients and referring veterinarians were contacted for follow-up; however, because long-term disease monitoring was at the discretion of the owner, recurrence could have been undetected in some patients.

Overall, the modified closed anal saccullectomy procedure was well tolerated in our study cohort and the short-term complication rate was low. The results supported that prospective clinical evaluation of the procedure with larger case numbers is warranted to allow an analysis that can be controlled for patient-specific factors, assess whether the technique provides a clinical benefit over more traditional anal saccullectomy methods, and investigate whether technique-specific adverse effects can be detected in dogs undergoing these procedures.

## Acknowledgments

The authors declare that there were no conflicts of interest.

Presented in part as a poster at the 30th European College of Veterinary Surgeons Annual Scientific Meeting (online), July 2021.

The authors thank Dr. Phil H. Hobson for teaching the modified technique described in this report and Tim Vojt for contribution to figures in the manuscript.

## References

1. Baker E. Diseases and therapy of the anal sacs of the dog. *J Am Vet Med Assoc.* 1962;141:1347-1350.
2. Greiner T, Johnson R, Betts C. Diseases of the rectum and anus. In: Ettinger S, ed. *Textbook of Veterinary Internal Medicine.* 2nd ed. Saunders; 1975:1505-1508.
3. Hill LN, Smeak DD. Open versus closed bilateral anal saccullectomy for treatment of non-neoplastic anal sac disease in dogs: 95 cases (1969-1994). *J Am Vet Med Assoc.* 2002;221(5):662-665.
4. Johnston D. Surgical diseases—rectum and anus. In: Slatter DH, ed. *Textbook of Small Animal Surgery.* Saunders; 1985:770-794.

5. Marretta S. Anal sac disease and removal. In: Bojrab J, ed. *Current Techniques in Small Animal Surgery*. Williams & Wilkins; 1998:283–286.
6. Matthiesen D, Marretta S. Diseases of the anus and rectum. In: Slatter DH, ed. *Textbook of Small Animal Surgery*. 2nd ed. Saunders; 1993:627–645.
7. Baines SJ, Aronson LR. Rectum, anus, and perineum. In: Tobias KM, Johnston SA, eds. *Veterinary Surgery: Small Animal*. Vol 2. 2nd ed. Elsevier; 2018:1783–1827.
8. Frye FL, Hoefl DJ, Cucuel JP, et al. Silicone sealant for preoperative packing of canine anal sacs. *J Am Vet Med Assoc*. 1970;156:1030–1031.
9. MacPhail C. Anal saccullectomy. *Compend Contin Educ Vet*. 2008;30(10):E9.
10. Seim H. Surgery of the feline anus and rectum. *Proc Post-Grad Comm Vet Sci-University Syd*. 1998;308:125–134.
11. Diaz D, Boston S, Ogilvie A, et al. Modified balloon-catheter-assisted closed anal saccullectomy in the dog: Description of surgical technique. *Can Vet J*. 2019;60(6):601–604.
12. Downs MO, Stampley AR. Use of a Foley catheter to facilitate anal sac removal in the dog. *J Am Anim Hosp Assoc*. 1998;34(5):395–397.
13. Follette CM, Giuffrida MA, Balsa IM, et al. A systematic review of criteria used to report complications in soft tissue and oncologic surgical clinical research studies in dogs and cats. *Vet Surg*. 2020;49(1):61–69.
14. Rosenthal R, Hoffmann H, Clavien PA, et al. Definition and classification of intraoperative complications (CLASSIC): Delphi study and pilot evaluation. *World J Surg*. 2015;39(7):1663–1671.
15. Strasberg SM, Linehan DC, Hawkins WG. The accordion severity grading system of surgical complications. *Ann Surg*. 2009;250(2):177–186.
16. Potanas CP, Padgett S, Gamblin RM. Surgical excision of anal sac apocrine gland adenocarcinomas with and without adjunctive chemotherapy in dogs: 42 cases (2005–2011). *J Am Vet Med Assoc*. 2015;246(8):877–884.
17. Skorupski KA, Alarcon CN, de Lorimier LP, et al. Outcome and clinical, pathological, and immunohistochemical factors associated with prognosis for dogs with early-stage anal sac adenocarcinoma treated with surgery alone: 34 cases (2002–2013). *J Am Vet Med Assoc*. 2018;253(1):84–91.

## Supplementary Materials

Supplementary materials are posted online at the journal website: [avmajournals.avma.org](http://avmajournals.avma.org)